PHCbi

70% of surveyed scientists admitted that they could not replicate someone else's research.[1]

50% admitted that they couldn't replicate their own research.[1]

Select from eight models including your choice of high heat or H_2O_2 decontamination with CO_2 or CO_2/O_2 control.

Improve Reproducibility.

PHCbi brand Cell-IQ™ CO_2 and O_2 incubators are designed to deliver reproducibility critical to immunotherapy and regenerative medicine from one day to the next.

Your desired temperature and gas concentrations replicate the *in vivo* model of any cell culture environment with precision and predictability. Our SafeCell™ and inCu-saFe® technologies protect your work *in vitro*. Learn more at **www.phchd.com/us/biomedical/cell-culture-incubators.**

PHC Corporation of North America

PHC Corporation of North America
1300 MIchael Drive, Suite A, Wood Dale, IL 60191
Toll Free USA (800) 858-8442, Fax (630) 238-0074
www.phchd.com/us/biomedical

1) Baker, Monya. "1,500 scientists lift the lid on reproducibility." Nature, no. 533 (May 26, 2016): 452-54. doi:10.1038/533452a.

PHC Corporation of North America is a subsidiary of PHC Holdings Corporation, Tokyo, Japan, a global leader in development, design and manufacturing of laboratory equipment for biopharmaceutical, life sciences, academic, healthcare and government markets.

Received: 9 July 2020 | Accepted: 17 November 2020
DOI: 10.1002/sctm.20-0308

HUMAN CLINICAL ARTICLES

STEM CELLS TRANSLATIONAL MEDICINE

Safety and efficacy of Wharton's jelly-derived mesenchymal stem cells with teriparatide for osteoporotic vertebral fractures: A phase I/IIa study

JeongHyun Shim[1] | Kyoung-Tae Kim[2,3] | Kwang Gi Kim[4,5] | Un-Yong Choi[6] | Jae Won Kyung[6] | Seil Sohn[6] | Sang Heon Lim[4] | Hyemin Choi[6] | Tae-Keun Ahn[7] | Hye Jeong Choi[8] | Dong-Eun Shin[7] | Inbo Han[6]

[1]Department of Neurosurgery, Shim Jeong Hospital, Seoul, South Korea

[2]Department of Neurosurgery, School of Medicine, Kyungpook National University, Daegu, South Korea

[3]Department of Neurosurgery, Kyungpook National University Hospital, Daegu, South Korea

[4]Department of Biomedical Engineering, College of Medicine, Gachon University, Seongnam-si, South Korea

[5]Department of Health Sciences and Technology, Gachon Advanced Institute for Health Sciences and Technology (GAIHST), Gachon University, Seongnam-si, South Korea

[6]Department of Neurosurgery, CHA University School of Medicine, CHA Bundang Medical Center, Seongnam-si, South Korea

[7]Department of Orthopedic Surgery, CHA University School of Medicine, CHA Bundang Medical Center, Seongnam-si, South Korea

[8]Department of Radiology, CHA University School of Medicine, CHA Bundang Medical Center, Seongnam-si, South Korea

Correspondence
Inbo Han, MD, PhD, Department of Neurosurgery, CHA University School of Medicine, CHA Bundang Medical Center, 59 Yaptap-ro, Bundang-gu, Seongnam-si, Gyeonggi-do 13496, South Korea.
Email: haninbo@gmail.com

Funding information
Ministry of Science and ICT (MSIT), Korea, Grant/Award Number: IITP-2020-2017-0-01630; Korea Health Technology Research and Development Project, Ministry for Health and Welfare Affairs, Grant/Award Numbers: HI20C0579, HI16C0106, HR16C0002

Abstract

Osteoporotic vertebral compression fractures (OVCFs) are serious health problems. We conducted a randomized, open-label, phase I/IIa study to determine the feasibility, safety, and effectiveness of Wharton's jelly-derived mesenchymal stem cells (WJ-MSCs) and teriparatide (parathyroid hormone 1-34) in OVCFs. Twenty subjects with recent OVCFs were randomized to teriparatide (20 μg/day, daily subcutaneous injection for 6 months) treatment alone or combined treatment of WJ-MSCs (intramedullary [4×10^7 cells] injection and intravenous [2×10^8 cells] injection after 1 week) and teriparatide (20 μg/day, daily subcutaneous injection for 6 months). Fourteen subjects (teriparatide alone, n = 7; combined treatment, n = 7) completed follow-up assessment (visual analog scale [VAS], Oswestry Disability Index [ODI], Short Form-36 [SF-36], bone mineral density [BMD], bone turnover measured by osteocalcin and C-terminal telopeptide of type 1 collagen, dual-energy x-ray absorptiometry [DXA], computed tomography [CT]). Our results show that (a) combined treatment with WJ-MSCs and teriparatide is feasible and tolerable for the patients with OVCFs; (b) the mean VAS, ODI, and SF-36 scores significantly improved in the combined treatment group; (c) the level of bone turnover markers were not significantly

Jeong Hyun Shim, Kyoung-Tae Kim and Kwang Gi Kim contributed equally.

This is an open access article under the terms of the Creative Commons Attribution-NonCommercial-NoDerivs License, which permits use and distribution in any medium, provided the original work is properly cited, the use is non-commercial and no modifications or adaptations are made.
© 2020 The Authors. STEM CELLS TRANSLATIONAL MEDICINE published by Wiley Periodicals LLC on behalf of AlphaMed Press

different between the two groups; (d) BMD T-scores of spine and hip by DXA increased in both control and experimental groups without a statistical difference; and (e) baseline spine CT images and follow-up CT images at 6 and 12 months showed better microarchitecture in the combined treatment group. Our results indicate that combined treatment of WJ-MSCs and teriparatide is feasible and tolerable and has a clinical benefit for fracture healing by promoting bone architecture. Clinical trial registration: https://nedrug.mfds.go.kr/, MFDS: 201600282-30937.

KEYWORDS
mesenchymal stem cells, osteoporosis, teriparatide, vertebral compression fracture, Wharton's jelly

1 | INTRODUCTION

Osteoporosis and osteoporotic fractures lead to decreased life quality and high health care costs. An osteoporotic fracture can be defined as a fracture resulting from a fall from a standing height or less, without major trauma such as a motor vehicle accident. Osteoporotic vertebral compression fractures (OVCFs) are the most common single osteoporotic fractures worldwide.[1-3] The incidence of OVCFs increases with age, with a higher rate in women than in men, and OVCFs carry an increased risk of mortality.[2] Osteoporosis is thought to be caused in part by a decreased number of mesenchymal stem cells (MSCs) and their preferential differentiation into adipocytes rather than osteoblasts in the aging skeleton.[4,5] This could lead to decreased osteoblast number and function and increased bone marrow fat in the aging bone.[4,6] Therefore, age-related decreases in MSC number and function may result in diminished bone formation and compromised bone microarchitecture, leading to further vertebral fractures and reduced fracture healing.[4,7]

The goals of treatment for OVCFs include back pain relief, restoration of function, and prevention of future fractures. Conservative treatments, including bed rest, pain medication, and a thoracolumbar hyperextension brace, are usually recommended to alleviate back pain. However, the failure of fracture healing after conservative treatment can lead to intractable back pain associated with nonunion and increased morbidity and mortality rates.[8] The incidence of nonunion after conservative treatments is approximately 13.5%.[8,9] Once nonunion advances to osteonecrosis and delayed vertebral collapse (Kummell's disease), the collapsed vertebrae causes a progressive kyphotic deformity and severe neural tissue compression with neurological deficits.[10,11] According to previous randomized controlled trials, vertebral augmentation procedures (percutaneous vertebroplasty or balloon kyphoplasty) cause serious complications, including bone cement leakage, infection, and pulmonary embolism,[8,12] and are not superior to sham procedures for pain relief.[8] In addition, vertebral augmentation procedures do not affect bone metabolism and cannot prevent new fractures, but they can increase the risk of adjacent vertebral compression fractures.[12] Therefore, vertebral augmentation procedures may be applied to control back pain for those in whom

Lessons learned

- Compared with bisphosphonate (antiresorptive drugs), teriparatide has been proven to induce bone formation through stimulation of osteoblast proliferation, prevention of osteoblast apoptosis, and increased osteoblast activity.
- The mechanism involved in bone formation of teriparatide is the activation of resident mesenchymal stem cells (MSCs); thus, teriparatide may be less effective in elderly patients with oteoporotic vertebral compression fractures (OVCFs) because of decreased MSC number and function.
- Combined treatments of Wharton's jelly-derived MSCs (WJ-MSCs) and parathyroid hormone (PTH) provided satisfactory functional improvement, including pain relief, increased bone density of fractured vertebra, and quality of life for patients with OVCFs at 1-year follow-up.
- The results indicate that combined treatment of WJ-MSCs and PTH is feasible and tolerable and has a clinical benefit for fracture healing by promoting bone architecture.

Significance statement

This study was designed as a randomized, open-label, phase I/IIa study in patients with osteoporotic vertebral compression fractures (OVCFs). Combined treatment with teriparatide and Wharton's jelly-derived mesenchymal stem cells (intramedullary [4×10^7 cells] injection, then, 1 week later, intravenous [2×10^8 cells] injection) provided satisfactory functional improvement, including pain relief and increased bone density of fractured vertebra, at 1-year follow-up. This is the first clinical trial of stem cells for patients with OVCF.

conservative treatment fails or, accompanying immobilization, carries serious risks.[12]

In terms of fracture healing after osteoporotic fractures, both MSCs and teriparatide (recombinant human parathyroid hormone [PTH] 1-34, an osteogenic osteoporosis agent) have been studied. Transplantation of MSCs has gained considerable attention to treat osteoporosis and OVCFs because implanted healthy MSCs could be differentiated into osteoblasts and reduce the susceptibility of fractures by facilitating new bone formation, as has been shown in animal studies.[4,7,13,14] Teriparatide is a form of PTH consisting of the first (N-terminal) 34 amino acids and is an effective anabolic agent. Compared with bisphosphonate (antiresorptive drugs), teriparatide has been proven to induce bone formation through stimulation of osteoblast proliferation, prevention of osteoblast apoptosis, and increased osteoblast activity.[11] In addition, teriparatide could be effective in preventing secondary OVCFs, increasing spine bone mineral density (BMD), and accelerating fracture healing and union rate in OVCFs.[11,15,16] Actually, the mechanism involved in bone formation of teriparatide is the activation of resident MSCs.[4,17,18] Thus teriparatide may be less effective in elderly patients with OVCFs because of decreased MSC number and function.[4,18] Therefore, combined treatments of MSCs and PTH have been tried to get a synergistic effect by enhancing MSC migration to heal bone loss, and the preclinical studies look promising.[18,19] However, no clinical trials exploring the effect of combined treatment of MSCs and PTH in patients with OVCFs have been performed. Thus, we conducted a proof-of-concept phase I clinical trial to assess the feasibility and efficacy of combined treatment with Wharton's jelly-derived MSCs (WJ-MSCs) and teriparatide (PTH 1-34) in patients with OVCFs.

2 | MATERIALS AND METHODS

2.1 | Study design

This was a 12-month open-label, randomized, controlled phase I/IIa study of combined treatment with WJ-MSCs and teriparatide in patients with recent single-level OVCFs. The present study was performed between July 2017 and June 2019 at CHA Bundang Medical Center in Seongnam, Korea. Subjects were strictly screened according to the inclusion and exclusion criteria as defined below. Subjects were originally randomized on a 1:1 basis to receive teriparatide 20 μg subcutaneously daily (Forteo, Eli Lilly & Co., Inc., Indianapolis, Indiana) or combined teriparatide and WJ-MSCs. All subjects in both control and experimental treatment groups received a subcutaneous injection of teriparatide (20 μg/day) for 6 months. However, all subjects in the experimental group underwent injection of 4×10^7 WJ-MSCs into the fractured vertebra at baseline (day 0) and intravenous injection of 2×10^8 cells WJ-MSCs at the first week (day 7). The primary aims of the study were to determine the safety and tolerability of WJ-MSCs in combination with teriparatide and to determine the clinical benefit of combination therapy on bone healing after OVCFs. The study protocol and subject informed consent documents were approved by the institutional review board (CHAMC 2015-11-204), and all participants provided written informed consent. The study was also approved by the Ministry of Food and Drug Safety of Korea (MFDS 201600282-30937) and was conducted in accordance with the Declaration of Helsinki. The study design is shown in Figure 1.

2.2 | Study population

Subjects with OVCFs admitted to the CHA Bundang Medical Center were eligible if they fulfilled the following inclusion criteria: (a) postmenopausal women aged between 50 and 89 years with at least 36 months since last menses; (b) a recent single-level OVCF between the fifth thoracic vertebra and fifth lumbar vertebra within 6 weeks after a low energy trauma, as shown by magnetic resonance imaging (MRI); (c) diagnosis of osteoporosis (BMD T-scores ≤−2.5 at the spine and total hip) using dual-energy x-ray absorptiometry (DXA); (d) back pain score ≥4 pain intensity on the 10-point pain visual analog scale (VAS); (e) Oswestry disability index (ODI) ≥30%; and (f) ability to provide written informed consent.

Subjects who had the following characteristics were excluded: (a) subjects who had taken antiosteoporotic drugs (bisphosphonate, selective estrogen receptor modulator, or parathyroid hormone) within 6 months of enrollment; (b) subjects with pathological vertebral fractures; (c) vertebral compression fracture with neurological deficit; (d) subjects who took drugs that affect bone metabolism, such as steroids; (e) subjects who underwent spinal fixation surgery at the vertebral fracture site prior to the clinical trial; (f) psychiatric disorders currently being treated, such as depression or schizophrenia; (e) participants in other clinical trials within 30 days of the start of the trial; and (f) severe comorbidities that could affect or interfere with therapeutic outcomes, including tumor, infection, uncontrolled hypertension and diabetes, renal disease, or liver disease. After informed consent was obtained, eligible subjects were randomized to teriparatide treatment alone or in combination with WJ-MSCs. A target sample size of 20 subjects randomized 1:1 to combination therapy or treatment with teriparatide alone was selected to be sufficient to provide an initial assessment of the safety and efficacy of combination therapy in patients with OVCFs. After random allocation, clinical, rheological, and radiological evaluations were performed at baseline and at 1, 3, 6, 9, and 12 months from the start of treatment.

2.3 | Preparation of WJ-MSCs

WJ-MSCs were provided by CHA Biotech, Co. Ltd. (Pangyo, Seongnam, Korea). Preparations of human WJ-MSCs were conducted in the Good Manufacturing Practices (GMP) facility, and the isolation and expansion of human WJ-MSCs were performed according to the Good Clinical Practice guidelines of the Master Cell Bank. The cells were suspended at a concentration of 2×10^7 cells per 1.0 mL of CryoStor CS10/vial. Safety was established through quality control of the final product based on analysis of genetic stability; fibroblastic

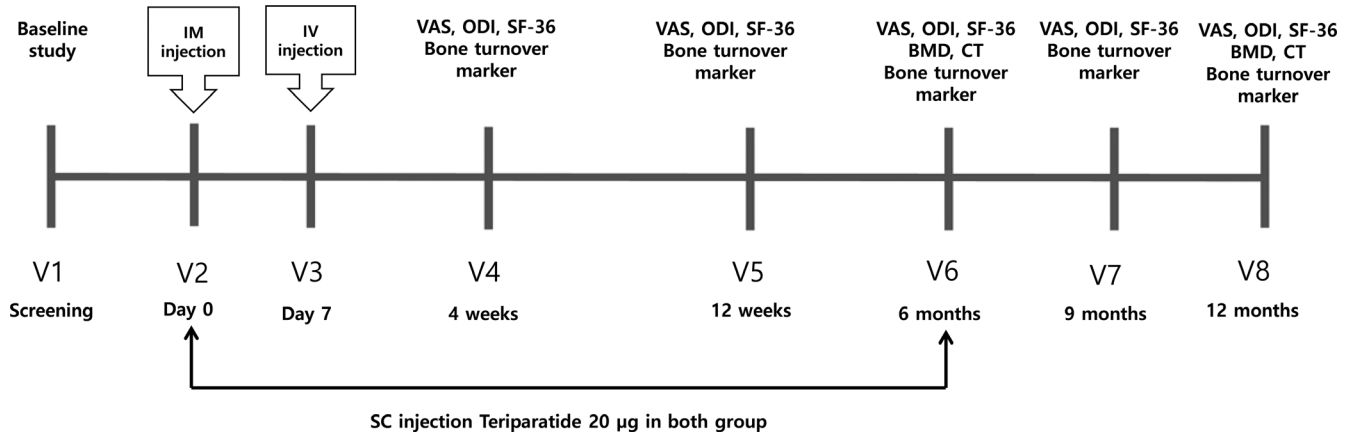

FIGURE 1 The study design. BMD, bone mineral density; CT, computed tomography; IM, intramedullary; IV, intravenous; ODI, Oswestry Disability Index; SC, subcutaneous; V1, visit 1- screening; V2, visit 2- stem cell injection into the fractured vertebra; V3, visit 3- intravenous stem cell injection; V4, visit 4- 4 weeks after stem cell injection; V5, visit 5- 12 weeks after stem cell injection; V6, visit 6- 6 months after stem cell injection; V7, visit 7- 9 months after stem cell injection; V8, visit 8- 12 months after stem cell injection; VAS, visual analog scale

morphology; microbiological, mycoplasma, and endotoxin contamination; purity; and cell count and viability. All of the WJ-MSCs used in this study were collected at passage 7. The cells were made and shipped on the day of injection.

2.4 | Interventions

All participants were admitted to CHA Bundang Medical Center because of recent OVCFs for about 2 weeks. After informed consent was obtained, 20 patients with new OVCFs were randomly allocated in a 1:1 ratio to receive either combination therapy or treatment with teriparatide alone. All subjects in both control and experimental treatment groups received a subcutaneous injection of 20 μg teriparatide once daily for 6 months, followed by oral administration of 20 mg bazedoxifene (Viviant, Pfizer, Inc., New York, New York) once daily for 6 months. All subjects and caregivers who administered teriparatide received appropriate training about how to inject teriparatide in the thigh or abdomen with a prefilled delivery device. The experimental treatment group received an intramedullary injection of 4×10^7 WJ-MSCs (direct injection into the recently fractured vertebra) at baseline (day 0). The procedures were done in the operating room. In brief, patients were in the prone position, and fractured vertebral bodies were identified under C-arm guidance. Infiltration of the skin entry site and muscles was performed with 1% lidocaine after draping with alcohol, and an 11 gauge Jamshidi bone marrow biopsy needle was advanced into the center of the fractured vertebra through the pedicle of the fractured vertebra under C-arm guidance. The cell product (2×10^7 cells per 1.0 mL of CryoStor CS10/vial) and fibrin glue (Greenplast kit, GC GreenCross Co., Youngin, Korea) were delivered to the operating room from the GMP facility. We implanted WJ-MSCS (2 vial, 4×10^7 cells) in combination with fibrin glue (2 mL) to prevent cell leakage into the center of the fractured vertebra. To minimize cell loss, the needle was left in place for 5 minutes. After stem cell implantation, the patient was monitored in the recovery room for 1 hour. One week later (day 7), the patient was transferred to the injection room for intravenous injection of WJ-MSCs (10 vial, 2×10^8 cells per 1.0 mL of CryoStor CS10/vial). The patients slowly underwent intravenous injection of stem cells for 1 hour and were closely monitored for the development of complications such as pulmonary embolism.

2.5 | Study assessments

The primary endpoints were assessments of the safety and tolerability of combined treatment of WJ-MSCs and teriparatide among individuals with recent OVCFs. Secondary endpoints that assessed the efficacy of teriparatide alone vs that of combined treatment included improvement of pain (VAS) and function (ODI, Short Form-36 [SF-36]), changes in BMD and serum levels of bone turnover markers (bone formation marker: osteocalcin; bone resorption marker: C-terminal telopeptide of type 1 collagen [CTX]) from the baseline at the 6- and 12-month time points after treatment initiation.

2.5.1 | Safety and tolerability

Safety and tolerability were assessed in all subjects who received teriparatide alone or combined treatment of teriparatide and WJ-MSCs at each visit. Study physicians assessed vital signs and laboratory examination of blood samples, adverse events (AEs), and serious AEs (SAEs) and determined whether each AE or SAE was related to the study treatment.

2.5.2 | Measurements of the impact on pain, function, and health-related quality of life

The impact of study treatment on pain, function, and health-related quality of life was assessed by a VAS, ODI, and SF-36 questionnaire from the baseline and at each visit (1, 3, 6, 9, and 12 months after treatment initiation). Differences in mean VAS, ODI, and SF-36 values between control and experimental treatment groups were evaluated.

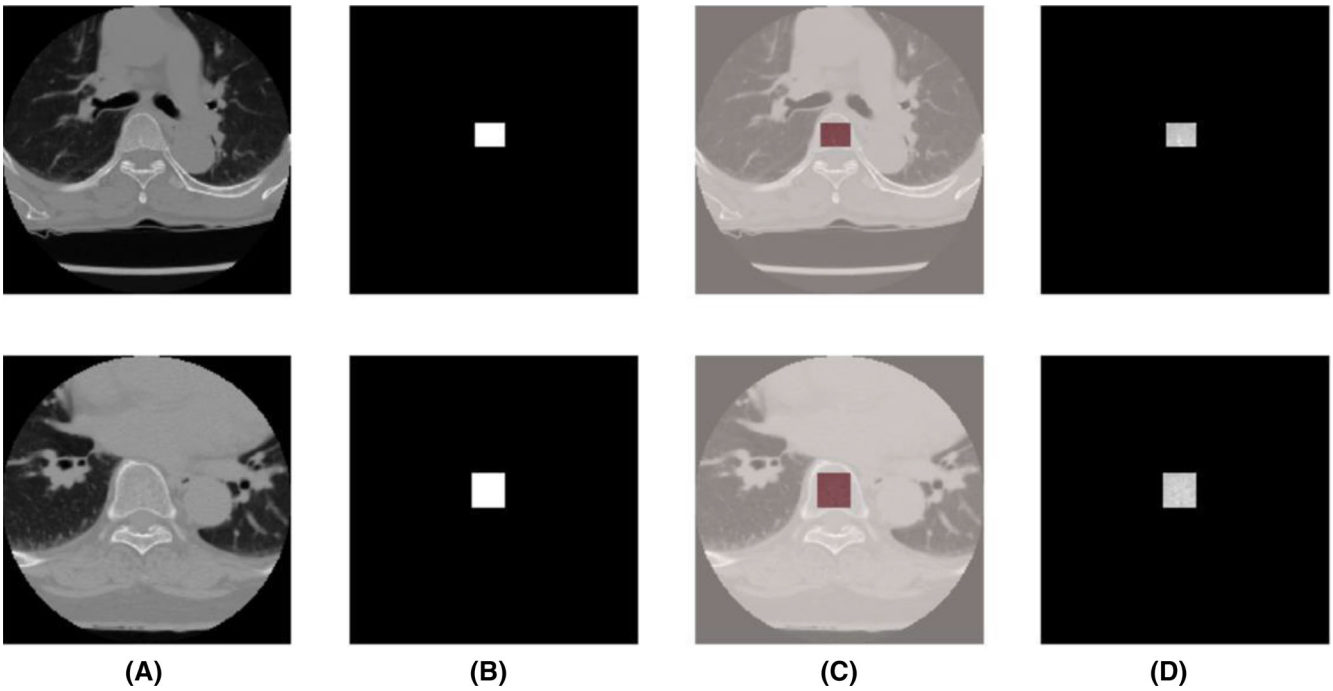

FIGURE 2 The process of extracting region of interest (ROI) using rectangle ROI mask. A, Normalized computed tomography image. B, Rectangle ROI mask. C, Overlay mask on image. D, Target region

2.5.3 | Bone mineral density measurements by DXA

BMD was measured at the posteroanterior lumbar spine, total hip, and femoral neck by DXA using a Hologic QDR 4500A densitometer (Hologic, Waltham, Massachusetts). All scans of individual subjects were performed on the same densitometer. Lumbar spine BMD was measured from lumbar 2 to lumbar 4 vertebral bodies. Differences in mean BMD T-scores between control and experimental treatment groups were evaluated at baseline and at the 6- and 12-month time points after treatment initiation.

2.5.4 | Bone turnover markers

Fasting morning blood samples were obtained at each visit (baseline, 3, 6, 9, and 12 months after treatment initiation). Serum osteocalcin, a marker for bone formation, was measured via electrochemiluminescent immunoassay (Meso Scale Discovery, Rockville, Maryland). Serum CTX, a marker for bone resorption, was measured via a fully automated electrochemiluminescent immunoassay (Roche Diagnostics, Indianapolis, Indiana).

2.5.5 | Computed tomography imaging of fractured vertebra

BMD can also be assessed with quantitative computed tomography (CT), but quantitative CT was not available for BMD measurements at our hospital. Spine CT was performed at baseline and 6-month and 12-month follow-ups to assess the occurrence of new fractures and fracture progression and to determine changes in BMD of the index level of the OVCF using radiomic feature extraction.[20-22] Via Picture Archiving and Communication System, the average Hounsfield unit (HU) was obtained. We collected axial images of the index level of the OVCFs at baseline and 6 and 12 months after treatment initiation (Figure 2). Because the HU of the CT images used in this study had a value of −1024 ~ 1024, it was normalized to a value of 0 ~ 255 pixels for the purpose of the extraction of radiomic features.[22] To analyze bone architecture from the normalized CT image, the region of interest (ROI) was defined as the rectangular box in an axial plane of the fractured vertebra, and the ROI was extracted using rectangle manual segmentation (Figure 2). Radiomic feature extraction was performed using the PyRadiomics 2.2.0 library to analyze the texture in the ROI and included first-order statistics and gray-level co-occurrence matrix (GLCM).[20,21] A total number of 43 features were extracted from each modality (first-order statistics: 19 features; GLCM: 24 features) Because the ROI mask in the form of a rectangle was used, shape features were not used. Detailed information on the radiomic features used in this study can be found at https://pyradiomics.readthedocs.io/en/latest/features.html.[23]

2.6 | Statistical analysis

Data are presented as means ± SD. Intergroup comparisons of categorical variables were performed using Fisher's exact test. The unpaired *t* test was used to analyze parametric continuous variables, and the Mann-Whitney *U* test was used to analyze nonparametric

continuous variables. The Wilcoxon signed-rank test and paired *t* test were used to compare pre- and post-treatment values (VAS, ODI, physical component summary, mental component summary, and BMD values). When tests were repeated measures, *P* values were corrected to adjust for multiple testing using the sequentially rejective Bonferroni method. For analyzing the significant difference BMD of fractured bone between the control and experimental groups, a two-way repeated measures analysis of variance (ANOVA) with two factors (month and feature value) was used.[24] Using the two-way repeated measures ANOVA, the *P* value was less than .05. It was interpreted that the control and experimental groups showed a significant difference, and the specific features were selected.

3 | RESULTS

3.1 | Baseline characteristics

Twenty-eight subjects with OVCFs were assessed for eligibility, and 20 subjects were enrolled through the randomization: 10 in the control group (teriparatide alone) and 10 in the experimental group (combined treatment with teriparatide and WJ-MSCs) (Figure 3). Of the 20 subjects enrolled in the study, 14 (control group, n = 7; experimental group, n = 7) completed a 12-month follow-up period. Three control subjects dropped out because of side effects of teriparatide including nausea, vomiting, and dizziness. In the experimental group, three subjects dropped out after intramedullary and intravenous injection of WJ-MSCs because of the following reasons: one subject withdrew her consent and underwent vertebroplasty in another hospital in the first month of follow-up, another subject did not come to the hospital at the 3-month visit and was lost to follow-up, and the other subject dropped out because of an incidental finding of pancreatic cancer in the first month of follow-up. Demographic characteristics for each group are presented in Table S1. There were no significant differences in the baseline characteristics between control and experimental groups.

3.2 | Safety outcome

AEs occurred in four (40%) subjects in the experiment group and three (30%) subjects in the control group (Table S2). According to the Common Terminology Criteria for Adverse Events (CTCAE), version 5.0, there were no grade 4 or 5 AEs. In the control group, three subjects complained of similar AEs such as nausea, vomiting, or dizziness after subcutaneous teriparatide injection, and they dropped out of the study. AEs or SAEs were found in four subjects in the experimental group. One subject was diagnosed with urinary tract infection due to *Candida albicans* 2 weeks after stem cell injection and fully recovered after antifungal therapy. However, the subject dropped out because of follow-up loss thereafter. Another subject complained of redness, itching, pain, and swelling at the site of injection after intravenous infusion of stem cells. The injection site reaction was mild and disappeared within 2 weeks. In another subject in the experimental group, pulmonary emboli were found on chest CT during the study. Five years before the start of the clinical trial, a lung examination was performed because of blood-tinged sputum and had shown no significant radiological findings. At day 30 after intravenous infusion of stem cells, a chest CT scan was performed because of blood-tinged sputum appearing after taking pain

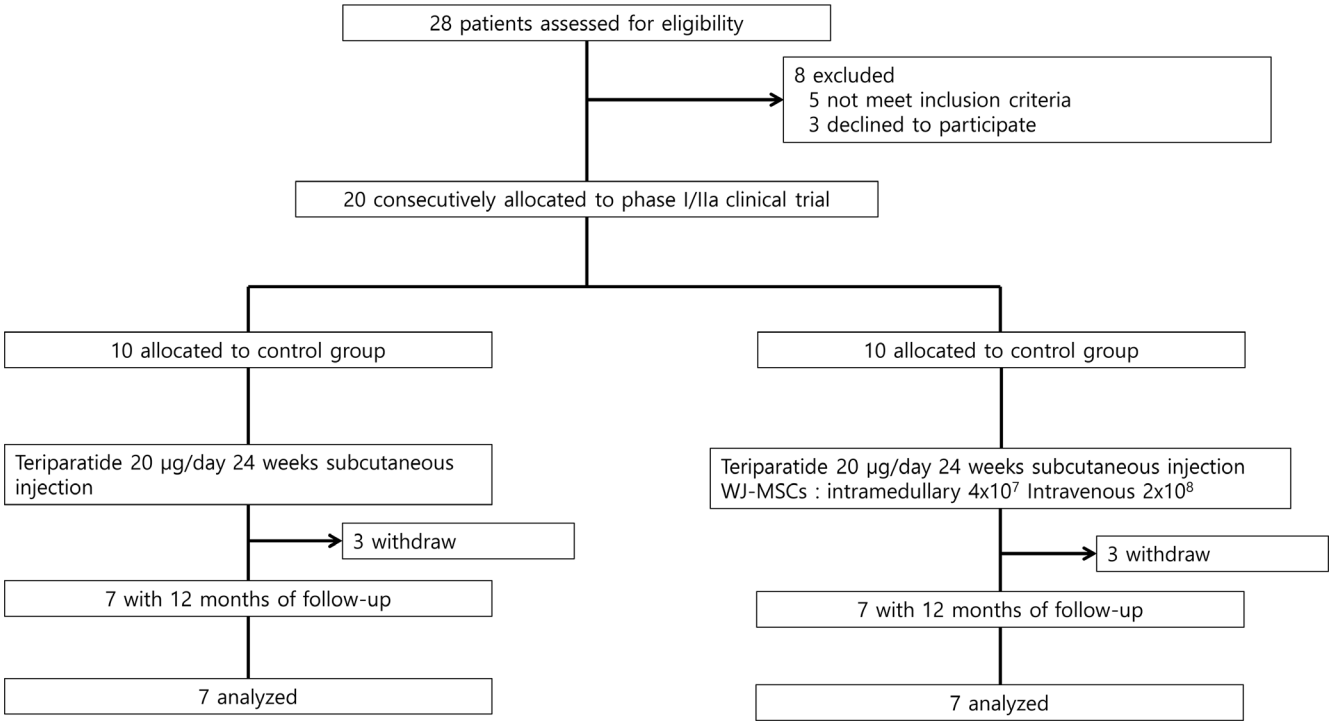

FIGURE 3 The study flow diagram. WJ-MSC, Wharton's jelly–derived mesenchymal stem cell

relief medications (Ultracet, Janssen, Titusville, New Jersey) and vomiting. It revealed pulmonary embolism (grade 3 by the CTCAE scale). So, the subject took rivaroxaban (15 mg twice a day, Xarelto, Bayer AG, Leverkusen, Germany) for 2 weeks and had no more significant blood in the sputum when clearing the throat during the study. The other subject in the experimental group was incidentally diagnosed with small pancreatic cancer (size 1.5 cm) because the subject underwent an abdomen CT scan because of acute epigastric pain at 3 months after stem cell injection. Gastrointesitinal endoscopy showed a gastric ulcer in the antrum, and MRI of the pancreas revealed a cancerous lesion in the pancreatic tail. The subject refused further assessment and treatment of pancreatic cancer and dropped out.

3.3 | Clinical outcomes

The mean ± SD VAS was 6.4 ± 1.1 in the experimental group and 7.1 ± 1.1 in the control group, and there was no statistical difference (P = .368) at baseline. From the first month of the treatment, the experimental group improved significantly compared with the control group. Although subjects in the control group improved during the study period, the pain score (VAS) in the experimental group significantly decreased over 12 months compared with that of the control group (Figure 4). The ODI for disability significantly decreased in both control and experimental groups, but the subjects in the experimental group significantly improved during the study period compared with the control group (experimental group: from 68.88 ± 19.81 to 17.77 ± 0.08; control group: from 81.22 ± 10.20 to 34.44 ± 9.81) (Figure 4). SF-36 was used to measure the quality of life. The physical component score at 12 months significantly increased from the baseline in both experimental and control groups (experimental group: from 16.6 ± 4.6 to 68.2 ± 12.6; control group: from 10.4 ± 3.9 to 40.2 ± 8.4). The mental component score at 12 months significantly increased from baseline in the experimental group. However, subjects in the control group did not significantly improve during the study period (Figure 4).

3.4 | Biomarkers for bone turnover

Figure 5A,B shows the median change in serum osteocalcin and CTX in the control and experimental groups during the 12-month

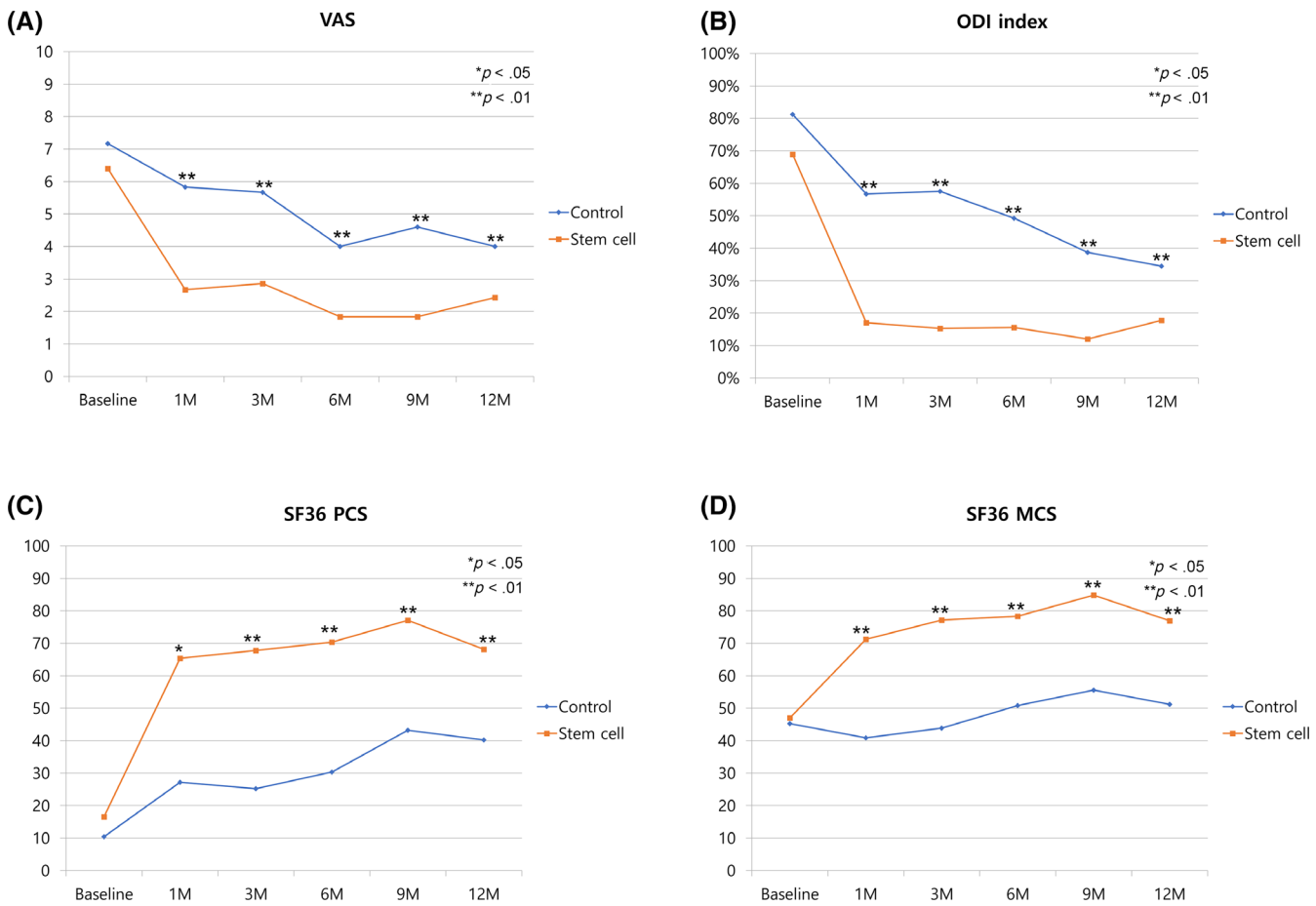

FIGURE 4 Changes in VAS, ODI, and SF-36 during the 12-month period in the control and experimental groups. A, VAS for back pain. B ODI. C, SF-36 physical component summary (PCS) score. D, SF-36 mental component summary (MCS) score. M, month; MCS, mental component summary; ODI, Oswestry Disability Index; PCS, physical component summary; SF-36, Short Form-36; VAS, visual analog scale

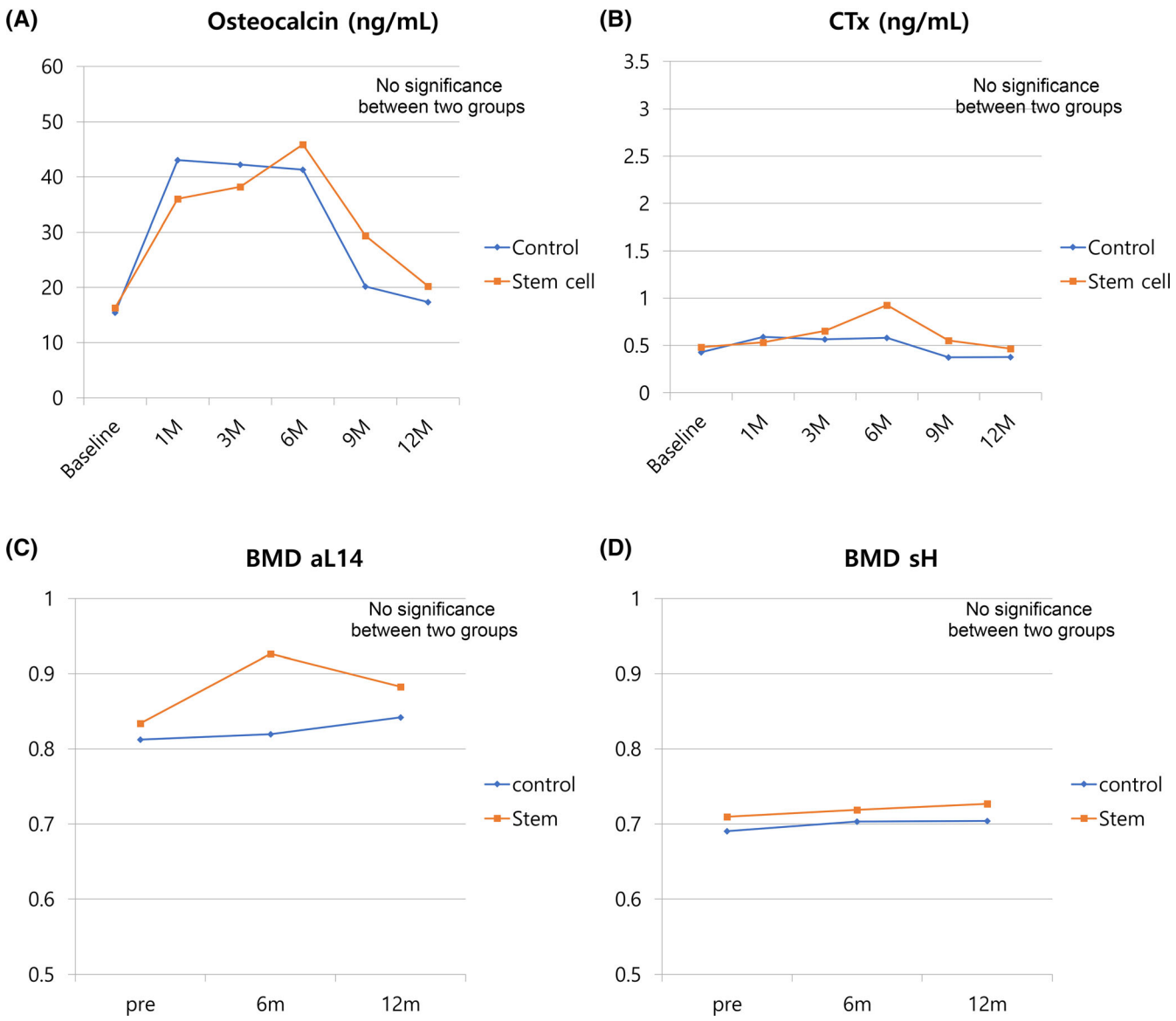

FIGURE 5 Changes in bone turnover markers and BMD during the 12-month period in the control and experimental groups. A, Changes in bone formation (osteocalcin) and bone resorption (CTX) markers. B, Changes in BMD. aL14, average BMD between L1 and L4; BMD, bone mineral density; CTX, C-terminal telopeptide of type 1 collagen; M, month; sH, single Hip BMD

follow-up period. The osteocalcin levels for the experimental and control groups were 16.3 ± 6.5 and 15.4 ± 4.7, respectively, at baseline (P = .795). The mean osteocalcin increased after treatment in both groups and was the highest at 6 months after treatment (45.9 ± 5.1 in the experimental group and 41.3 ± 15.0 in the control group) and then gradually decreased until final follow-up. The two groups showed similar patterns and did not show statistical differences. Mean changes in the bone resorption marker CTX in the experimental and control groups were 0.48 ± 0.16 and 0.42 ± 0.14, respectively, at baseline (P = .537). After treatment, the two groups showed an increase in CTX up to 6 months, which then decreased and showed no statistical difference.

3.5 | BMD by DXA

Figure 5C–E shows the median change in BMD in the control and experimental groups during the 12-month follow-up period. BMD was measured by three methods, the lowest value in the lumbar spine, the mean value from lumbar 1 to lumbar 4, and the value in the left femur neck. The lowest value BMD in spine improved from 0.72 ± 0.15 to 0.78 ± 0.19 in the experimental group and improved from 0.65 ± 0.15 to 0.77 ± 0.15 in the control group, with no statistical difference between the two groups. For the mean BMD of lumbar 1 to lumbar 4, the experimental group increased from 0.84 ± 0.19 to 0.91 ± 0.24 and the control group increased from 0.82 ± 0.13 to 0.91 ± 0.16, with no statistical difference between the two groups. Hip BMD showed

similar results. The experimental and control groups were, respectively, 0.70 ± 0.07 and 0.72 ± 0.08 at baseline and 0.70 ± 0.13 and 0.64 ± 0.19 at the last follow-up, with no statistical difference between the two groups.

3.6 | Difference in BMD of fractured vertebra by CT

We found no occurrence of new fracture and fracture progression along a sagittal plane. The results of feature analysis using a two-way repeated measures ANOVA are shown in Table S3, and the feature values using PyRadiomics are shown by the variance charts of 10th percentile, mean, and energy (Figure 6). For the repeated measures ANOVA, a significant difference between the control and experimental groups was shown with a *P* value of less than .05 for 10th percentile, mean, and energy. In the experimental group, all three feature values significantly increased compared with the control group. The results indicate that combined treatment of WJ-MSCs and teriparatide significantly increased BMD of the fractured vertebra compared with teriparatide treatment alone. Figure 7 reveals representative CT images of the control and experimental groups at baseline and at 6- and 12-month follow-ups.

4 | DISCUSSION

The most common type of osteoporotic fracture is OVCF, affecting nearly 25% of the elderly population who are older than 50 years.[1,25] OVCF raises the risk for new vertebral fractures 5fold in the first year, and the presence of two or more OVCFs increases the risk up to 12-fold.[26] The number of subsequent fractures is associated with increased mortality risk.[15] Back pain that persists after an OVCF is partly associated with vertebral instability (nonunion or slow-forming union) at the fractured site, which may require surgical intervention such as vertebroplasty or spinal reconstruction. In addition, once nonunion of OVCF progresses to vertebral osteonecrosis, the collapsed vertebrae cause neurological deficits resulting from a progressive

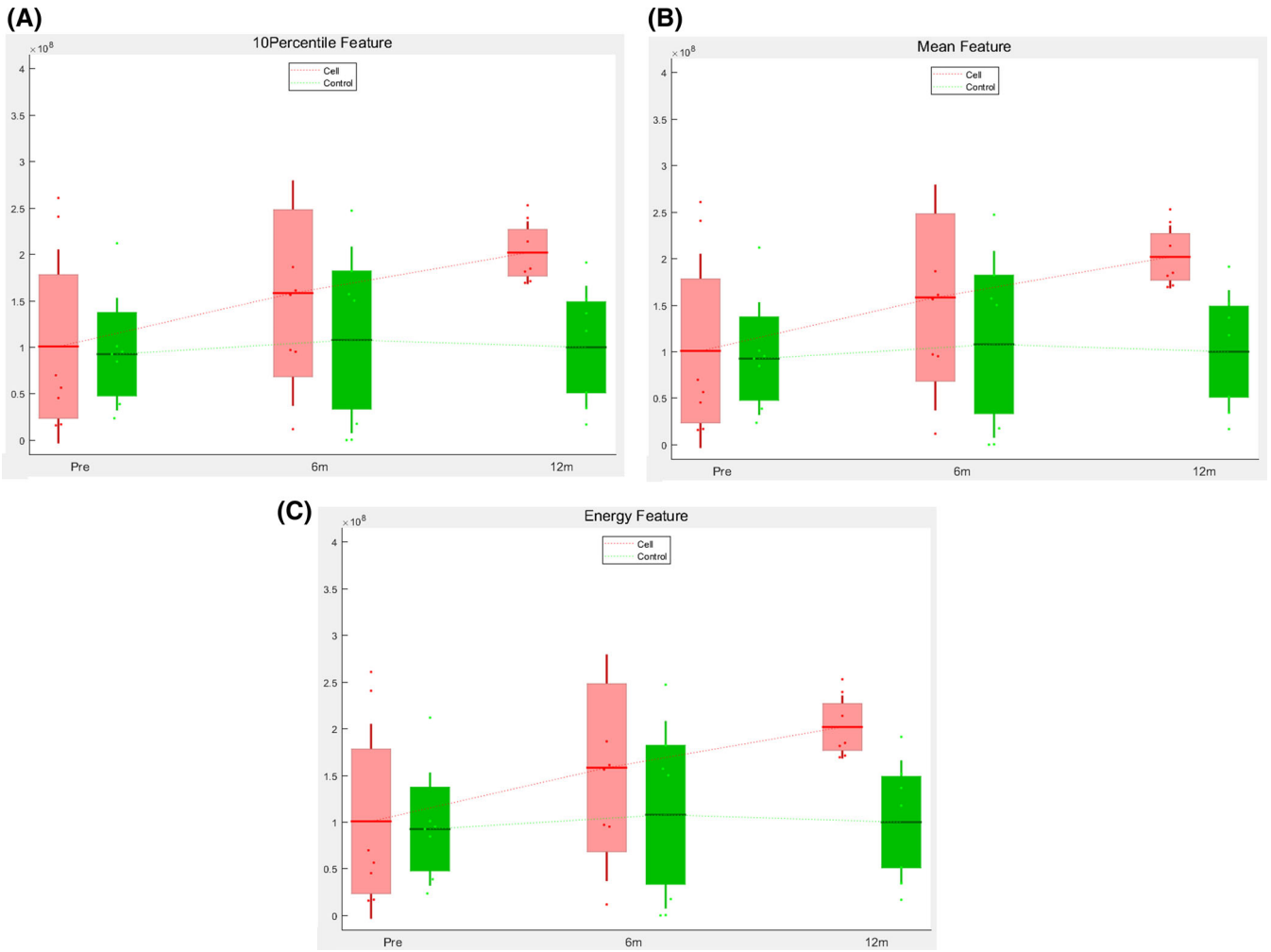

FIGURE 6 The variance chart of mean, 10% percentile, and energy feature. A, Variance chart of mean feature. B, Variance chart of 10% percentile feature. C, Variance chart of energy feature

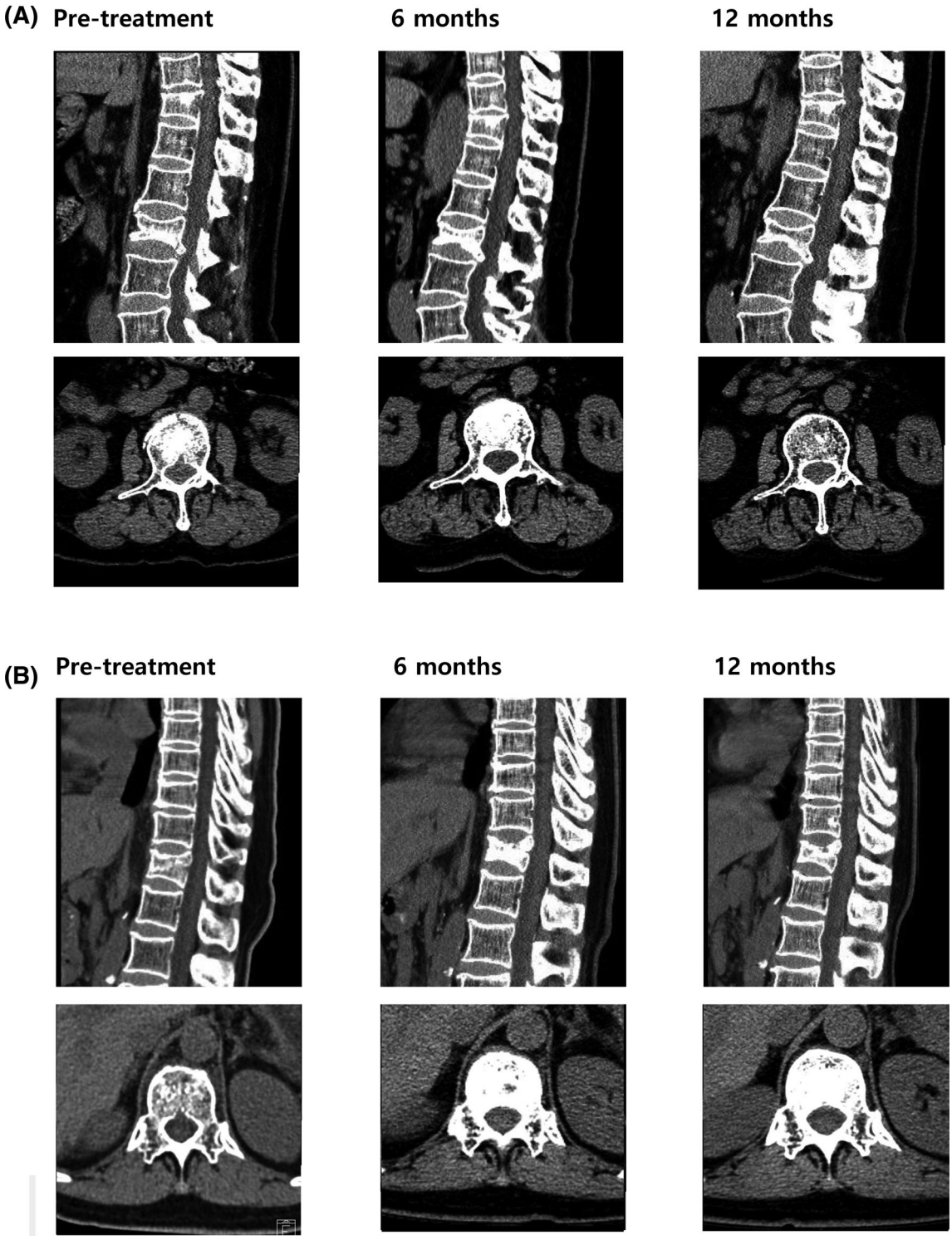

FIGURE 7 Representative computed tomography (CT) images of the control and experimental groups at baseline and at 6 and 12 months. A, Representative CT images of the control group. B, Representative CT images of the experimental group

kyphotic deformity and severe neural tissue compression.[10,11] Therefore, the top priority in the treatment of OVCF is to ensure fracture healing and preventing secondary OVCFs.[8,11]

In this study, we compared the efficacy of the combined injection of WJ-MSCs and teriparatide to that of teriparatide treatment alone. The primary findings of this study were as follows: (a) combined treatment with WJ-MSCs and teriparatide is feasible and tolerable for the treatment of OVCFs; (b) the mean scores of VAS, ODI, and SF-36 significantly improved in the combined treatment group; (c) the level of bone turnover markers (osteocalcin and CTX) were not significantly

different between the two groups; (d) BMD T-scores of spine and hip by DXA increased in both control and experimental groups with no significant difference; and (e) baseline spine CT images and follow-up CT images at 6 and 12 months showed better microarchitecture of fractured vertebrae in the experimental group. Our results indicate that combined treatment of WJ-MSCs and teriparatide in OVCF patients is feasible and tolerable and combined injection may be more effective for fracture healing by promoting bone architecture.

MSCs are promising candidates for bone regeneration therapies. However, the main therapeutic limitations of MSC therapy for OVCFs include selection of optimal MSCs, selection of best administration route, insufficient homing, engraftment, and osteogenic differentiation. WJ-MSCs were chosen for this study because WJ-MSCs are known to have a high proliferation rate and wide multipotency, hypoimmunogenicity, and immunomodulatory potential compared with MSCs derived from other sources.[27-30] WJ-MSCs express low levels of human leukocyte antigen (HLA) class I and no HLA-DR leading to low immunogenicity. Additionally, WJ-MSCs bear better immunomodulatory potential and anti-inflammatory effects by suppressing mitogen-induced T-cell responses to a greater extent than MSCs from either bone marrow or adipose tissue.[31] In this study, the control group received only teriparatide (subcutaneous, 6 months, PTH), and the experimental treatment group received teriparatide (subcutaneous, 6 months) and stem cell injections (intramedullary injection of WJ-MSCs [direct injection into the recently fractured vertebra] at baseline and intravenous injection at 7 days after intramedullary injection).

The appropriate route of stem cell administration is an essential step for a successful treatment. Osteoporosis is a systemic disease, characterized by a decrease in bone mass and a deterioration in bone microstructure leading to an increased risk of bone fractures.[32] In elderly patients with osteoporosis, the number of osteoblast progenitor MSCs is decreased, and the capacity of MSCs to differentiate into osteoblasts was found to be lower than that from healthy people.[32] It has been shown that intravenous transplantation of MSCs significantly increased BMD in osteoporotic animals.[32] On the other hand, MSCs were also known to have no capability of spontaneous engraft and differentiation at osteoporotic bone areas. Thus, direct intrabone implantation of bone marrow-derived MSCs has been reported to achieve long-term engraftment (up to 6 months postimplantation), with the consequent improvement of cortical structure and strength in mouse bone.[5,33] Additionally, Sheyn et al demonstrated that intravenous injection of MSCs and PTH in the treatment of osteoporotic vertebral bone defect significantly increased new bone formation compared with MSC monotherapy, and PTH was found to induce significant migration of systemically administered MSCs to the vertebral bone defect area.[18] In addition, many researchers emphasize early fracture healing after OVCFs to prevent subsequent recurrent fractures.[34] PTH was shown to induce fracture repair in animals by activating MSCs, and MSCs can also enhance bone repair by modulating the process of inflammation.[18,34] Therefore, we injected PTH and WJ-MSCs and used two routes of administration of MSCs (intramedullary and intravenous).

Osteoporosis is characterized by low bone strength, which is determined by not only bone mass but also bone quality. Bone mass is mainly expressed by BMD, and bone quality is composed of microarchitecture, bone turnover rate, mineralization, and microdamage accumulation.[35] Bone turnover markers have been used for monitoring early responses to antiosteoporosis therapy because of a delayed response of BMD to clinical treatment. Because both BMD and bone turnover markers are independent and essential, many researchers have tried to study the relationship between the changes in bone turnover markers and BMD in treated and untreated patients with osteoporosis. However, the results of these studies are sometimes controversial and generally exhibit significant disparity across studies.[36] It has been reported that there is a rapid rise in bone formation marker during the first month of teriparatide treatment and a subsequent increase in bone resorption markers during the entire 24-month treatment course, and the increase in bone formation markers exceeds increases in bone resorption markers during the entire 24-month treatment course.[37] In this study, the levels of bone formation (osteocalcin) and resorption (CTX) markers were not significantly different between the control and experimental groups. In the control group, the levels of osteocalcin and CTX increased at 1 month after treatment initiation, maintained similar levels up to 6 months, and gradually decreased. However, there seemed to be a more rapid rise in osteocalcin compared with CTX. These findings are consistent with previous reports demonstrating that increases in bone formation markers exceeded increases in CTX.[37] In the experimental group, osteocalcin increased rapidly at 1 month after stem cell injection, gradually increased up to 6 months, and then gradually decreased, whereas CTX gradually increased up to 6 months and gradually decreased, showing that the increase in osteocalcin exceeded the increase in CTX during the study. Both control and experimental groups showed that early significant increases in osteocalcin (bone formation marker) were followed by a subsequent increase in CTX (bone resorption marker), showing that the increase in the bone formation marker exceeded the increase in the bone resorption marker during the study. BMD T-scores of spine and hip have been reported to increase significantly after 24 months of treatment with teriparatide.[37-39] In terms of the effect of stem cell implantation on BMD, preclinical studies of the therapeutic role of stem cell therapy in animal models of osteoporosis have shown inconsistent results, but a meta-analysis showed that stem cell implantation was associated with significantly improved BMD as compared with that observed in controls in animal models of osteoporosis.[13] In this study, BMD T-scores of the spine and hip by DXA increased in both the control and experimental groups, but there was no significant difference between them.

The risk factors for vertebral nonunion have been reported to be associated with thoracolumbar fracture, decreased BMD, and posterior wall fracture.[9] Especially, BMD was negatively correlated with the osteonecrosis (intervertebral vacuum) occurrence rate.[9,39] Thus, sensitive detection of changes in BMD is a key issue in monitoring and evaluating the individual bone health status as well as bone metabolism and bone mineral status.[40] Additionally, bone microarchitecture is very important for the treatment of osteoporosis and OVCF and

assessment of bone microarchitecture in complement to a BMD exam could improve the prediction of OVCFs.[41] Texture analysis has been reported to be independent and complementary with BMD for determining the odds ratio of fractures.[41,42] Therefore, we assessed bone microarchitecture in complement to BMD using radiomics-based feature extraction after collecting baseline CT images and follow-up CT images at 6 months and 12 months.[41,43,44] Repeated measures ANOVA showed significant differences in 10th percentile, mean, and energy. Here, the 10th percentile is the tenth lowest intensity value in the ROI of the axial plane at the index level of the OVCF. The result can be interpreted as showing that the overall BMD increased in the area with a low BMD. The mean value means the average intensity value inside the ROI, and as this value increases, it can be interpreted as showing that the BMD of the index level of OVCF increased on average. Energy is a value representing the sum of the total intensity value of the vertebral region of interest, and as this value increases, it can be interpreted as showing that the sum of the total BMD of the index level of OVCF increased. Thus, our radiomic feature analyses show that combined injection of WJ-MSCs and teriparatide may accelerate fracture healing by improving bone microarchitecture of the fractured vertebra (Figure 6).

MSCs have been reported to be a new therapeutic strategy to treat osteoporosis and OVCF, mainly because of their ability to secrete factors that are directly or indirectly involved in bone repair, as well as their ability to graft into tissues and differentiate into functional osteoblasts. Emerging evidence suggests that inflammation exerts a significant influence on bone turnover, thereby in osteoporosis.[5] Once the bone repair process has started, the inflammatory response must be stopped to avoid more damage.[5] In this study, intravenous injection of WJ-MSCs (2×10^8 cells) occurred 1 week after intramedullary injection (4×10^7 cells) because osteoporosis is a systemic skeletal disease. The exact mechanism by which the combined injection of WJ-MSCs and teriparatide led to improvement of back pain and bone microarchitecture of the fractured vertebra in the present study remains unclear. Although we found no significant difference in BMD by DXA between control and experimental groups in this study, we assume that teriparatide enhances WJ-MSCs migration into the fractured vertebra and differentiation of WJ-MSCs into osteoblasts and intramedullary and intravenous injection of WJ-MSCs improve fracture healing by inhibiting inflammatory response.[5,18,19]

In terms of AEs, stem cell injection-related AEs were reported in two subjects in the experimental group. After intravenous injection, one subject complained of an injection site reaction, which was mild and disappeared within 2 weeks. The other subject was diagnosed with pulmonary embolism at day 30 after intravenous infusion of stem cells. Actually, intravenous injection of MSCs leads to the accumulation of fewer than 10% of administered MSCs, with many cells captured in the lung.[33] In this study, all subjects in the experimental group did not undergo a chest CT scan. One subject had a medical history of blood-tinged sputum 5 years before the start of the study and underwent chest CT because of blood-tinged sputum when clearing the throat 30 days after intravenous infusion of cells. The subject had no signs and symptoms of pulmonary embolism, such as recurrent blood-tinged sputum during the study, and completed participation in this clinical trial. The other subject in the experimental group dropped out because of a cancerous lesion in the pancreatic tail at 3 months after stem cell injection. One subject with blood-tinged sputum when clearing the throat might suffer from a chronic pulmonary embolism,[45] and the other subject (an 82-year-old female) with pancreatic cancer might suffer from a cancer-related aging process. However, intravenous infusion of MSCs could result in pulmonary embolism and even death in an animal study, and MSCs could cause the development of tumor tissue.[34,46] Thus, we could not entirely exclude the possibility of complications (pulmonary embolism, pancreatic cancer), and we should pay careful attention to possible complications such as pulmonary embolism and tumor formation in MSC therapy. We also strongly recommend screening chest CT prior to enrollment and follow-up chest CT in case of intravenous injection of MSCs.

Our study is a randomized, open-label, phase I/IIa study to determine the feasibility and efficacy of combined treatment of WJ-MSCs and PTH in OVCFs, and thus caution should be applied when drawing any conclusions regarding long-term safety and efficacy. In addition, our study has limitations including a limited experimental group with a small number of participants, an absence of animal study, and insufficient examination of bone turnover markers. In this study, we did not include subjects who received WJ-MSCs monotherapy and included only subjects with PTH monotherapy and subjects with combined treatments of WJ-MSCs and PTH. Based on the literature[18] showing that MSC monotherapy was less effective for repairing osteoporotic vertebral bone defect compared with combined treatments of WJ-MSCs and PTH, we did not include a WJ-MSC monotherapy group. Second, we did not complete an animal study to explore possible mechanisms of combined treatments of WJ-MSCs and PTH, including paracrine action of transplanted WJ-MSCs and bone formation resulting from engraftment of cells and differentiation into osteoblasts. Third, we checked only two bone turnover markers (osteocalcin and CTX) in our study. Bone turnover markers have been used as short-term tools for monitoring the adherence and response to treatment with antiosteoporotic agents. Unfortunately, the levels of bone turnover markers are highly variable according to multiple contributors such as patients and time for measurements.[47-49] Factors that can be adjusted and minimized, termed controllable factors, include circadian rhythm variations, food intake, exercise level, alcohol intake, seasonal variation, and medications such as oral glucocorticoids and aromatase inhibitors.[48,49] Factors contributing to preanalytical variability that cannot be controlled, known as uncontrollable factors, include age, degree of mobility/immobility, ethnicity, presence of fracture, and menopausal state. Additionally, the amino-terminal propeptide of type 1 procollagen (P1NP), the preferred marker for bone formation, is more stable compared with osteocalcin,[47] but we did not measure the P1NP level because our hospital did not provide services for measuring P1NP. Therefore, large-scale clinical trials assessing the optimal cell dose, optimal cell administration routes, optimal biomaterials loaded with stem cells, and relevant clinical endpoints are needed to define the long-term safety and efficacy of cell therapy for OVCFs. However, we propose that

combined treatments of WJ-MSCs and PTH may provide a feasible and tolerable treatment for OVCFs.

5 | CONCLUSION

Combined treatments of WJ-MSCs and PTH provided satisfactory improvement of pain, function, and quality of life for patients with OVCFs at the 12-month follow-up. Therefore, combined treatment of WJ-MSCs and PTH is feasible and tolerable and has a clinical benefit for fracture healing by promoting bone architecture.

ACKNOWLEDGMENTS

This research was supported by Korea Health Technology Research and Development Project, Ministry for Health and Welfare Affairs (HR16C0002, HI16C0106, HI20C0579) and supported by the Ministry of Science and ICT (MSIT), Korea, under the Information Technology Research Center (ITRC) support program (IITP-2020-2017-0-01630) supervised by the Institute for Information and Communications Technology Promotion (IITP).

CONFLICT OF INTEREST

The authors declared no potential conflicts of interest.

AUTHOR CONTRIBUTIONS

J.H.S.: collection and/or assembly of data, manuscript writing, final approval of manuscript; K.T.-K. and K.G.K.: data analysis and interpretation, manuscript writing, final approval of manuscript; U.-Y.C., J.W.K., S.S., S.H.L., H.C., H.J.C., and D.-E.S.: data analysis and interpretation, final approval of manuscript; T.-K.A.: collection and/or assembly of data, final approval of manuscript; I.H.: conception/design, collection and/or assembly of data, manuscript writing, final approval of manuscript.

DATA AVAILABILITY STATEMENT

The data that support the findings of this study are available from the corresponding author upon reasonable request.

ORCID

Un-Yong Choi https://orcid.org/0000-0001-9331-1112
Inbo Han https://orcid.org/0000-0002-6434-0245

REFERENCES

1. Ballane G, Cauley JA, Luckey MM, et al. Worldwide prevalence and incidence of osteoporotic vertebral fractures. *Osteoporos Int*. 2017;2:1531-1542.
2. Cauley JA, Chalhoub D, Kassem AM, Fuleihan GEH. Geographic and ethnic disparities in osteoporotic fractures. *Nat Rev Endocrinol*. 2014;10:338-351.
3. Mizutani J, Inoue N, Otsuka Y, Furuya A, Espinoza Orias AA, Otsuka T. Biomechanical and anatomical validity of the short posterior arch screw. *Neurospine*. 2019;16:347-353.
4. Cheng C, Wentworth K, Shoback DM. New frontiers in osteoporosis therapy. *Annu Rev Med*. 2020;71:277-288.
5. Macías I, Alcorta-Sevillano N, Rodriguez CI, et al. Osteoporosis and the potential of cell-based therapeutic strategies. *Int J Mol Sci*. 2020;21:1653.
6. Hu L, Yin C, Zhao F, Ali A, Ma J, Qian A. Mesenchymal stem cells: cell fate decision to osteoblast or adipocyte and application in osteoporosis treatment. *Int J Mol Sci*. 2018;19:360.
7. Sanghani-Kerai A, McCreary D, Lancashire H, Osagie L, Coathup M, Blunn G. Stem cell interventions for bone healing: fractures and osteoporosis. *Curr Stem Cell Res Ther*. 2018;13:369-377.
8. Ma Y, Wu X, Xiao X, et al. Effects of teriparatide versus percutaneous vertebroplasty on pain relief, quality of life and cost-effectiveness in postmenopausal females with acute osteoporotic vertebral compression fracture: a prospective cohort study. *Bone*. 2020;131:115154.
9. Zhang L, Wang T, Chang M, et al. Teriparatide treatment improves bone defect healing via anabolic effects on new bone formation and non-anabolic effects on inhibition of mast cells in a murine cranial window model. *J Bone Miner Res*. 2017;32:1870-1883.
10. Hoshino M, Nakamura H, Terai H, et al. Factors affecting neurological deficits and intractable back pain in patients with insufficient bone union following osteoporotic vertebral fracture. *Eur Spine J*. 2009;18:1279-1286.
11. Iwata A, Kanayama M, Oha F, Hashimoto T, Iwasaki N. Effect of teriparatide (rh-PTH 1-34) versus bisphosphonate on the healing of osteoporotic vertebral compression fracture: a retrospective comparative study. *BMC Musculoskelet Disord*. 2017;18:148.
12. Martikos K, Greggi T, Vommaro F, et al. Vertebroplasty in the treatment of osteoporotic vertebral compression fractures: patient selection and perspectives. *Open Access Rheumatol*. 2019;11:157-161.
13. Li F, Zhou C, Xu L, Tao S, Zhao J, Gu Q. Effect of stem cell therapy on bone mineral density: a meta-analysis of preclinical studies in animal models of osteoporosis. *PLoS One*. 2016;11:e0149400.
14. Pelled G, Sheyn D, Tawackoli W, et al. BMP6-engineered MSCs induce vertebral bone repair in a pig model: a pilot study. *Stem Cells Int*. 2016;2016:6530624.
15. Jin YZ, Lee JH, Xu B, Cho M. Effect of medications on prevention of secondary osteoporotic vertebral compression fracture, non-vertebral fracture, and discontinuation due to adverse events: a meta-analysis of randomized controlled trials. *BMC Musculoskelet Disord*. 2019;20:399.
16. Shigenobu K, Hashimoto T, Kanayama M, Ohha H, Yamane S. The efficacy of osteoporotic treatment in patients with new spinal vertebral compression fracture pain, ADL, QOL, bone metabolism and fracture-healing - in comparison with weekly teriparatide with bisphosphonate. *Bone Rep*. 2019;11:100217.
17. Jiang X, Xu C, Shi H, Cheng Q. PTH1-34 improves bone healing by promoting angiogenesis and facilitating MSCs migration and differentiation in a stabilized fracture mouse model. *PLoS One*. 2019;14:e0226163.
18. Sheyn D, Shapiro G, Tawackoli W, et al. PTH induces systemically administered mesenchymal stem cells to migrate to and regenerate spine injuries. *Mol Ther*. 2016;24:318-330.
19. Makihara T, Yoshioka T, Sugaya H, et al. Feasibility and efficacy of autologous bone marrow aspirate transplantation combined with human parathyroid hormone 1-34 administration to treat osteonecrosis in a rabbit model. *Bone Marrow Res*. 2017;2017:2484689.
20. Zulpe N, Pawar V. GLCM textural features for brain tumor classification. *Int J Comput Sci Issues*. 2012;9:354-359.
21. Mackin D, Fave X, Zhang L, et al. Measuring CT scanner variability of radiomics features. *Invest Radiol*. 2015;50:757-765.
22. Ada & Kaur, R. Feature extraction and principal component analysis for lung cancer detection in CT images. *International Journal of Advanced Research in Computer Science and Software Engineering*. 2013;3(3). https://www.semanticscholar.org/paper/Feature-Extraction-and-Principal-Component-Analysis-Kaur-Guru/cb7e5e6f426153fde5bd6a61ee299c4d0e4d740e.

23. van Griethuysen JJM, Fedorov A, Parmar C, et al. Computational radiomics system to decode the radiographic phenotype. *Cancer Res*. 2017;77:e104-e107.
24. Potvin PJ, Schutz RW. Statistical power for the two-factor repeated measures ANOVA. *Behav Res Methods Instrum Comput*. 2000;32:347-356.
25. Li H, Yang DL, Ma L, Wang H, Ding WY, Yang SD. Risk factors associated with adjacent vertebral compression fracture following percutaneous vertebroplasty after menopause: a retrospective study. *Med Sci Monit*. 2017;23:5271-5276.
26. Lindsay R, Silverman SL, Cooper C, et al. Risk of new vertebral fracture in the year following a fracture. *JAMA*. 2001;285:320-323.
27. Ahn J, Park EM, Kim BJ, et al. Transplantation of human Wharton's jelly-derived mesenchymal stem cells highly expressing TGFbeta receptors in a rabbit model of disc degeneration. *Stem Cell Res Ther*. 2015;6:190.
28. Liu S, Hou KD, Yuan M, et al. Characteristics of mesenchymal stem cells derived from Wharton's jelly of human umbilical cord and for fabrication of non-scaffold tissue-engineered cartilage. *J Biosci Bioeng*. 2014;117:229-235.
29. Mallis P, Michalopoulos E, Chatzistamatiou T, Stavropoulos-Giokas C. Mesenchymal stromal cells as potential immunomodulatory players in severe acute respiratory distress syndrome induced by SARS-CoV-2 infection. *World J Stem Cells*. 2020;12:731-751.
30. Batsali AK, Kastrinaki MC, Papadaki HA, et al. Mesenchymal stem cells derived from Wharton's jelly of the umbilical cord: biological properties and emerging clinical applications. *Curr Stem Cell Res Ther*. 2013;8:144-155.
31. Choi UY, Joshi HP, Payne S, et al. An injectable hyaluronan-methylcellulose (HAMC) hydrogel combined with Wharton's jelly-derived mesenchymal stromal cells (WJ-MSCs) promotes degenerative disc repair. *Int J Mol Sci*. 2020;21:7391.
32. Paspaliaris V, Kolios G. Stem cells in osteoporosis: from biology to new therapeutic approaches. *Stem Cells Int*. 2019;2019:1730978.
33. Sinder BP, Novak S, Wee NKY, et al. Engraftment of skeletal progenitor cells by bone-directed transplantation improves osteogenesis imperfecta murine bone phenotype. *STEM CELLS*. 2020;38:530-541.
34. Loi F, Cordova LA, Pajarinen J, et al. Inflammation, fracture and bone repair. *Bone*. 2016;86:119-130.
35. Park SY, Ahn SH, Yoo JI, et al. Position statement on the use of bone turnover markers for osteoporosis treatment. *J Bone Metab*. 2019;26:213-224.
36. Hong L, Liu D, Wu F, Wang M, Cen Y, Ma L. Correlation between bone turnover markers and bone mineral density in patients undergoing long-term anti-osteoporosis treatment: a systematic review and meta-analysis. *Appl Sci*. 2020;10:832.
37. Lindsay R, Krege JH, Marin F, Jin L, Stepan JJ. Teriparatide for osteoporosis: importance of the full course. *Osteoporos Int*. 2016;27:2395-2410.
38. Boonen S, Marin F, Obermayer-Pietsch B, et al.; EUROFORS InvestigatorsEffects of previous antiresorptive therapy on the bone mineral density response to two years of teriparatide treatment in postmenopausal women with osteoporosis. *J Clin Endocrinol Metab*. 2008;93:852-860.
39. Ettinger B, San Martin J, Cran G, et al. Differential effects of teriparatide on BMD after treatment with raloxifene or alendronate. *J Bone Miner Res*. 2004;19:745-751.
40. Mao SS, Li D, Syed YS, et al. Thoracic quantitative computed tomography (QCT) can sensitively monitor bone mineral metabolism: comparison of thoracic QCT vs lumbar QCT and dual-energy x-ray absorptiometry in detection of age-relative change in bone mineral density. *Acad Radiol*. 2017;24:1582-1587.
41. Lespessailles E, Gadois C, Lemineur G, Do-Huu JP, Benhamou L. Bone texture analysis on direct digital radiographic images: precision study and relationship with bone mineral density at the os calcis. *Calcif Tissue Int*. 2007;80:97-102.
42. Benhamou CL, Poupon S, Lespessailles E, et al. Fractal analysis of radiographic trabecular bone texture and bone mineral density: two complementary parameters related to osteoporotic fractures. *J Bone Miner Res*. 2001;16:697-704.
43. He L, Liu Z, Liu C, Gao Z, Ren Q, Lei L, Ren J. Radiomics based on lumbar spine magnetic resonance imaging to detect osteoporosis. *Acad Radiol*. 2020;S1076-6332(20)30192-6. [Online ahead of print].
44. Rastegar S, Vaziri M, Qasempour Y, et al. Radiomics for classification of bone mineral loss: a machine learning study. *Diagn Interv Imaging*. 2020;101:599-610.
45. Castaner E, Gallardo X, Ballesteros E, et al. CT diagnosis of chronic pulmonary thromboembolism. *Radiographics*. 2009;29:31-50.
46. Barkholt L, Flory E, Jekerle V, et al. Risk of tumorigenicity in mesenchymal stromal cell-based therapies–bridging scientific observations and regulatory viewpoints. *Cytotherapy*. 2013;15:753-759.
47. Wheater G, Elshahaly M, Tuck SP, Datta HK, van Laar JM. The clinical utility of bone marker measurements in osteoporosis. *J Transl Med*. 2013;11:201.
48. Szulc P, Naylor K, Hoyle NR, et al. National Bone Health Alliance Bone Turnover Marker Project. Use of CTX-I and PINP as bone turnover markers: National Bone Health Alliance recommendations to standardize sample handling and patient preparation to reduce pre-analytical variability. *Osteoporos Int*. 2017;28:2541-2556.
49. Szulc P, Naylor K, Pickering ME, Hoyle N, Eastell R, Leary E. Use of CTX-I and PINP as bone turnover markers: National Bone Health Alliance recommendations to standardize sample handling and patient preparation to reduce pre-analytical variability. *Ann Biol Clin (Paris)*. 2018;76:373-391.

SUPPORTING INFORMATION

Additional supporting information may be found online in the Supporting Information section at the end of this article.

How to cite this article: Shim JH, Kim K-T, Kim KG, et al. Safety and efficacy of Wharton's jelly-derived mesenchymal stem cells with teriparatide for osteoporotic vertebral fractures: A phase I/IIa study. *STEM CELLS Transl Med*. 2020; 1–14. https://doi.org/10.1002/sctm.20-0308